

# The Importance of Early Diagnosis for Hydroxyapatite Remineralisation in Enamel Caries

LAURA CIRLIGERIU<sup>1</sup>, COSMIN SINESCU<sup>1</sup>, MARIUS BOARIU<sup>1</sup>, MEDA-LAVINIA NEGRUTIU<sup>1</sup>, LUMINITA NICA<sup>1\*</sup>

<sup>1</sup> "Victor Babes" University of Medicine and Pharmacy, Faculty of Dental Medicine, 9 Revolutiei 1989 Blv., 300070, Timisoara, Romania

*The aim of the present study is to compare the effectiveness of the diagnosis with a clinical examination, digital imaging fiber-optic transillumination (DIFOTI) technology (DIAGNOcam) and X-ray examination in proximal caries diagnosis of permanent dentition. Fifteen adult patients were examined. They were first visual examined under magnification. After that, a diagnosis with DIAGNOcam was performed. Bitewing X-ray images were administered. The data from the three diagnostic methods was compared. The visual examination seriously underestimated lesions involving only enamel. In these cases there was a good correlation between DIFOTI and X-ray data but DIFOTI is more accurate compared to bitewing radiography because the extension of tooth structure demineralization can be more precise to evaluate and helps in determining the treatment course, non-invasive approach through remineralisation or minimally-invasive intervention.*

**Keywords:** remineralisation, hydroxyapatite, fluoride, DIFOTI, incipient carious lesions, bitewing X-rays

Dental caries on proximal tooth surface constitutes a large health problem for high-risk patients; at the age of 20 years, up to 50% of patients show carious or restored proximal surfaces [1]. Discovering a frank cavity is not equivalent to caries diagnosis, and if it is defined as an intellectual course of collecting and consolidating data obtained by clinical and radiographic examination along with the use of objective diagnostic armamentarium, biologic knowledge, and information gained from anamnesis — is still a combination of art and science and it will be much more than detecting breakdown of surfaces [2].

Proximal caries diagnosis and staging assessment is still a challenge in many industrialized countries and the lack of compliance with preventive behavior by patients is still a major problem, so it is important to diagnose proximal caries in early stages (limited to enamel) in order to arrest and control them so they can benefit of a much more tissue-preserving approach similar to preventive treatment methods. These methods include increasing biofilm pH and the resistance of the tooth surface to demineralization, limiting pathogen growth and altering metabolism. In this study we emphasize the importance enamel resistance to demineralization and early lesions remineralisation, restoring the enamel. If fluoride ions participate in this process, enamel will not only be restored, but resistance to new acid attacks increases. Below a critical pH of 5.5, hydroxyapatite minerals acts like a buffer system losing the calcium ions and phosphate ions in the bacterial biofilm.

This buffer capacity of the tooth maintain the local pH at about 5, which is responsible for the characteristic histologic appearance of the enamel carious lesion. At low pH of 3 or 4 the enamel surface is demineralized and rough. At pH 5 the tooth surface remains intact, while the subsurface minerals are dissolved and the initial carious lesion confined to the enamel is characterized by a virtual surface intact, but with a porous subsurface. The intact surface is a critical issue for potential remineralisation process because it protects the partial demineralized

hydroxyapatite crystals which, from the beginning, are plated with salivary proteins. These hydroxyapatite crystals remain open and may precipitate more if local surrounding conditions changes and the supersaturation of the saliva with calcium and phosphate ions serves as a driving force for the remineralisation process.

If a series of demineralizations (when pH decreases) and remineralisation (due to salivary ions) occurs, the episodes are dominated by the demineralization process. Fluoride plays a very important role in this process of demineralization - remineralisation. In acidic environment, fluoride ions react with the calcium ions and free phosphate ions, forming crystals of fluorapatite  $\text{Ca}_{10}(\text{PO}_4)_6(\text{OHF})_2$ , where the fluorine substitutes a part of the hydroxyl groups. Due to a better arrangement of the subunits, fluorapatite is less soluble than pure hydroxyapatite. Fluorapatite crystals are not dissolved by acidic ions at a pH above 4.5 (fluorapatite critical pH), resulting in an increased resistance to the dissolution of the mineral in an acidic environment. It is known as well, that fluoride has an antimicrobial activity. In low concentrations of fluoride ions inhibits the enzymatic production of glycosyltransferases, which promote extracellular polysaccharide to form glucose, which increase bacterial adhesion to enamel surface. The formation of intracellular polysaccharides is inhibited as well, preventing the storage of carbohydrates by limiting microbial metabolism between the patient meals. Thus, in our study, we focus on early diagnosis of noncavitated enamel caries lesion of the proximal tooth surfaces which are particularly susceptible to caries because of the extra shelter provided to the resident cariogenic biofilm, and at this stage, can benefit both from the remineralisation and antimicrobial effect of the fluoride which is a totally non-invasive treatment approach.

Currently, the diagnostic of carious lesions includes visual, tactile and radiographic examination. Often, these traditional methods are not sensitive enough to detect carious lesions limited to the enamel. Digital imaging fiber-optic transillumination (DIFOTI) allows an early diagnosis in order to approach a remineralisation treatment for the carious process to become reversible [3].

\* email: luminita.nica98@yahoo.ro

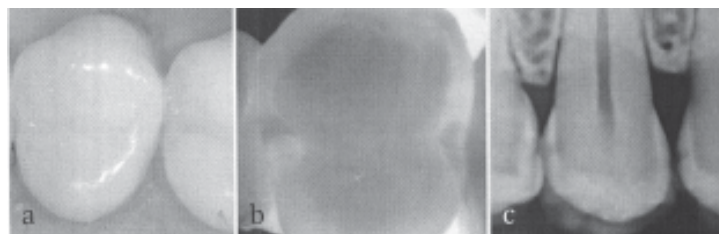


Fig. 1. The clinical aspect (a), the DIAGNOcam image (b) and the radiographic image (c) of the tooth 1.5. mesial

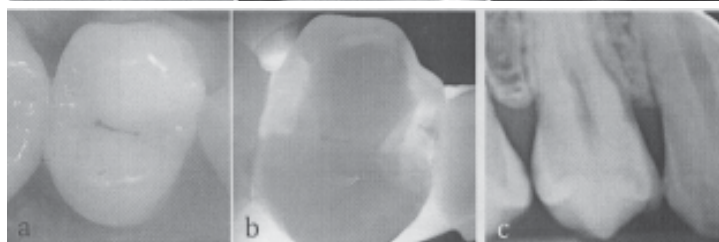


Fig. 2. The clinical aspect (a), the DIAGNOcam image (b) and the radiographic image (c) of the tooth 1.4. mesial

### Experimental part

The present study aims to evaluate the correlation between digital imaging fiber-optic transillumination (DIFOTI) [4], clinical examination and digital bitewing radiographic images in early proximal carious lesions diagnosis, in posterior teeth in order to provide clinical recommendations because it is now recognized that demineralized but noncavitated enamel lesions can be arrested or remineralized in many situations [5].

Posterior caries susceptible teeth were examined on a number of 15 patients, aged between 20 and 35 years (12 female, 3 male) and were evaluated 24 proximal carious lesions on these patients.

Following the patient screening and their consent to participate in the study, on all patients was performed professional cleaning and the interdental spaces were visually examined with a dental mirror and a probe then X-ray images of the bitewings were performed and analysed.

After this all the patients were examined using the newly developed DIAGNOcam (KaVo, Biberach, Germany) [6]. The results obtained were then compared to the clinical examination results and to the X-ray based examination of proximal surfaces of the permanent dentition [7].

DIAGNOcam (KaVo, Biberach, Germany) is a laser diode system with the wavelength of 780 nm that uses the structures of the tooth as light conductors and takes advantage of these optical properties of enamel and enhances them by using a high intensity white light and grey scale camera that is shone through the tooth and the scattering effect can be seen as shadows in enamel and dentine, with the device's ability to help discriminate

between early enamel and early dentine lesions, being particularly useful at proximal lesions. Images are displayed on a computer monitor and can be archived for retrieval at a repeat visit [8].

Carious lesions are displayed as dark shadows, and the images recorded by the KaVo DIAGNOcam can be stored, thus significantly simplifying monitoring and patient communication.

### Results and discussions

According to Classification of DIAGNOcam Findings, first detectable signs of an enamel caries lesion, established enamel caries lesion and established enamel caries lesion which reached the EDJ at a single point could benefit of caries monitoring and preventive intervention. [9].

The clinical situation (fig. 1.a, 2.a, 3.a, 5.a) indicates a caries-free proximal tooth surface. When the DIAGNOcam procedure is used, caries can be diagnosed either on the mesial and the distal surface (fig. 1.b, 2.b, 3.b, 5.b); in none of the cases is the dentine-enamel junction implicated. Although the corresponding bitewing X-ray image can not be evaluated due to the projection conditions (fig. 1.c, 2.c, 3.c, 5.c). Apart from occlusal browning, (fig.4.a) a clinical investigation of premolar 4.5. does not identify any other signs of carious processes. In contrast, the DIAGNOcam image (fig.4.b) points out extensive distal shadowing, which has already extended to the dentine-enamel junction. Instead, the associated bitewing X-ray picture (fig.4.c) points to a carious process limited to enamel. The visual diagnosis of another premolar 4.5. (fig. 6.a) indicates no signs of proximal caries and the bitewing X-ray picture is not relevant (fig. 6.c). Instead the

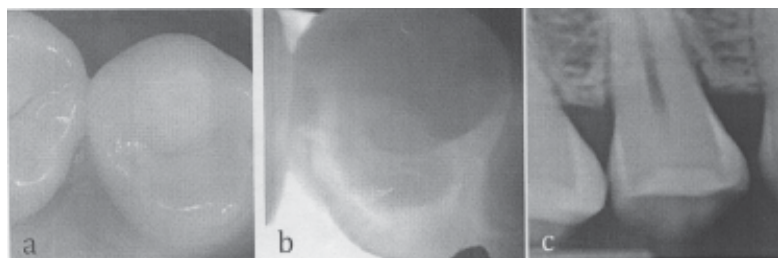


Fig. 3. The clinical aspect (a), the DIAGNOcam image (b) and the radiographic image (c) of the tooth 1.4. distal

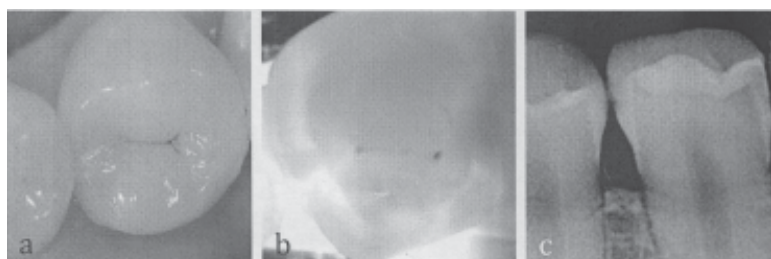


Fig. 4. The clinical aspect (a), the DIAGNOcam image (b) and the radiographic image (c) of the tooth 4.5. mesial

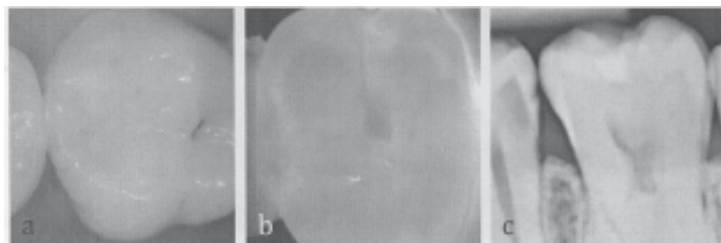


Fig. 5. The clinical aspect (a), the DIAGNOcam image (b) and the radiographic image (c) of the tooth 1.6. mesial

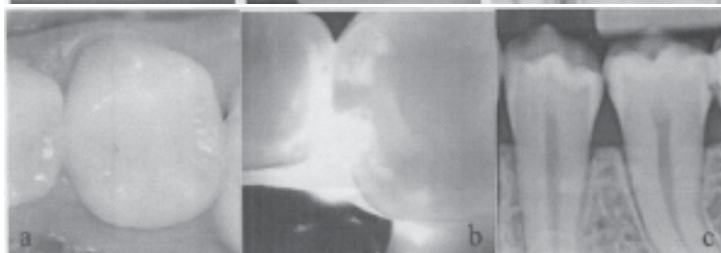


Fig. 6. The clinical aspect (a), the DIAGNOcam image (b) and the radiographic image (c) of the tooth 4.5. mesial

DIAGNOcam image (fig. 6.b) shows an established enamel caries which reached the EDJ at a single point. This caries lesion still benefit, according to the DIAGNOcam manufacturer, of intensive profilactic treatment on order to achieve remineralisation.

The evaluation of the results obtained with DIAGNOcam method allowed the identification of 14 proximal incipient carious lesions which through visual examination could not have been detected and the X-rays were inconclusive.

Early caries detection and quantification of lesions to establish their progression or arrest is crucial if dental approach is going to be changed from mainly operative to preventive. Early caries diagnosis is also important for clinical dental researches - the ability of accurate detection and determination of the size of early lesions may permit the use of shorter intervals and lesser number of patients to assess the effectiveness of caries preventive measures.

The method is more accurate compared to bitewing radiography, the extension of tooth structure demineralization can be evaluate and helps in determining the treatment course, non-invasive approach through remineralisation or minimally-invasive intervention, knowing the fact that more of 50% of proximal lesions showing on radiography that invaded the dentin in the external half are noncavitated [10].

The further procedure is to include preventive support of caries monitoring, which is eminently possible with the DIAGNOcam procedure [11] because it can be used for observing the effects of an intensive prophylactic program.

## Conclusions

Based on the present examination data, it can be concluded that visual examination proved to be an insufficient method for detection of proximal non-cavitated lesions involving only enamel. The examination method using DIAGNOcam shows higher sensitivity in detecting incipient proximal caries not apparent to X-ray and not seen visually. We could recommend DIAGNOcam to be used in combination with the visual method as an alternative of Rx examination.

This system also allows comparison of at least two consecutive evaluation of the same site within a few months and could indicate the level of caries activity. However, there is no attempt within the software to quantify the images, and analysis is still undertaken visually by the examiner who makes a subjective call based on the appearance of scattering [11].

DIAGNOcam represent a useful tool in diagnosis and evaluation of the incipient carious lesions which can benefit

of a noninvasive treatment in order to achieve remineralisation. Moreover, the advantages of DIFOTI over radiography include no ionizing radiation and real-time diagnosis.

*Acknowledgement: This paper was supported by the project Competitia interna PIII-C2-PCFI-2015/2016, acronim DENTALOCT, titlul: "Fundamentari inovative si aplicative ale tomografiei optice coerente in medicina dentara. Validari experimentale alternative" and by Romanian Authority for Scientific Research under Partnership grant CNDI-UEFISCDI PN-II-PT-PCCA-2011-3.2-1682, CONTRACT NR. 22/2012*

## References

1. MEJARE, I., KALLESTAL, C., STENLUND, H., Incidence and pro-gression of approximal caries from 11 to 22 years of age in Sweden: A prospective radiographic study. *Caries Res* 1999;33:93-100.
2. KIELBASS, A.M., Current challenges in caries diagnosis. *Quintessence Int* 2006;37:421.
3. ARDELEAN, S., CÎRLIGERIU, L., SINESCU, C., JUMANCA, D., LERETTER, M., NEGRUIU, M.L., The usage of digital imaging fiber-optic transillumination in association with laser-fluorescence as a complementary method in proximal carious lesions diagnosis, *Medicine in Evolution* 2014;XX(2):122.
4. GUTIERREZ, C., DIFOTI (Digital Fiberoptic Transillumination): Validitat In Vitro, Dissertation Zum Erwerb des Doktorgrades der Zahnheilkunde an der Medizinischen Fakultät der Ludwig-Maximilians-Universität zu München, 2008.
5. KIELBASSA, A.M., MÜLLER, J., R.GERNHARDT, C., mClosing the gap between oral hygiene and minimally invasive dentistry: A review on the resin infiltration technique of incipient (proximal) enamel lesions. *Quintessence Int* 2009;40(8):663.
6. \*\*\* Information on <http://www.kavo.com/Products/Diagnostics/DIAGNOcam.aspx>.
7. KÜHNISCH, J., Study Project "Benefits of the DIAGNOcam Procedure for the Detection and Diagnosis of Caries", Summary of the Final Report, Munich, December 2013.
8. PRETTY, I.A., Caries detection and diagnosis: Novel technologies. *Journal of dentistry* 2006;34:733-734.
9. \*\*\* Information on <http://www.kavo.com/Products/Diagnostics/DIAGNOcam/Downloads.aspx>.
10. DOVE SB, Radiographic diagnosis of caries. *J Dent Educ* 65:985-990, 2001
- 11.\*\*\* Information on <http://www.kavo.com/Products/Diagnostics/DIAGNOcam/Surveys-clinic/Clinical-case-studies.aspx>
12. SCHNEIDERMAN, A., ELBAUM, M., SHULTZ, T., KEEM, S., GREENEBAUM, M., DRILLER, J., Assessment of dental caries with digital imaging fiber-optic transillumination (DIFOTI): in vitro study. *Caries Research* 1997;31(2):103-10.

Manuscript received: 2.09.2014